

Intracranial Atherosclerotic Stenosis: An Up-to-Date Review

--Manuscript Draft--

Article Type:	Review article
Keywords:	intracranial atherosclerotic disease; ischemic stroke; intracranial atherosclerotic stenosis
Corresponding Author:	Cindy Diaz, Subspecialist Instituto Nacional de Neurología y Neurocirugía Manuel Velasco Suárez: Instituto Nacional de Neurología y Neurocirugía Manuel Velasco Suarez Bogota, Bogota COLOMBIA
First Author:	Cindy Andrea Diaz, M.D
Order of Authors:	Cindy Andrea Diaz, M.D
	Cindy Diaz, Subspecialist
	Jorge Balderrama
	Alba Herrera, Subspecialist
	Alfredo Montenegro
Abstract:	<p>Cerebrovascular accidents (CVA) or strokes are one of the main mortality and morbidity causes around the world. Large-vessel atherosclerosis represents 20% of ischemic strokes (IS), 50% are intracranial, and it is associated with a high risk of recurrent CVA compared with other CVA subtypes, despite even the best medical care. Intracranial atherosclerotic disease (ICAD) is one of the main causes of IS, representing almost 5-10% of intracranial atherosclerotic strokes in the USA, and up to 50% in Asia.</p> <p>In this review, we discuss recent clinical assays that have contributed to understanding the disease process associated with ICAD, risk factors associated with CVA recurrence in this subgroup of patients, imaging characteristics related to the prognosis, and an update on the treatments that reduce CVA recurrence.</p>
Suggested Reviewers:	

Abstract

Cerebrovascular accidents (CVA) or strokes are one of the main mortality and morbidity causes around the world. Large-vessel atherosclerosis represents 20% of ischemic strokes (IS), 50% are intracranial, and it is associated with a high risk of recurrent CVA compared with other CVA subtypes, despite even the best medical care (1). Intracranial atherosclerotic disease (ICAD) is one of the main causes of IS, representing almost 5-10% of intracranial atherosclerotic strokes in the USA, and up to 50% in Asia (2).

In this review, we discuss recent clinical assays that have contributed to understanding the disease process associated with ICAD, risk factors associated with CVA recurrence in this subgroup of patients, imaging characteristics related to the prognosis, and an update on the treatments that reduce CVA recurrence.

Intracranial Atherosclerotic Stenosis: An Up-to-Date Review

Cindy Díaz¹, Jorge Balderrama², Alba Herrera³, Alfredo Montenegro⁴

¹ Neurology, Endovascular Therapy Fellowship, Universidad Javeriana, Colombia, Universidad Nacional Autónoma de México, Instituto Nacional de Neurología y Neurocirugía Manuel Velasco (INNN)

^{2,4} Neuroradiology, Endovascular Therapy, Universidad Nacional Autónoma de México, Instituto Nacional de Neurología y Neurocirugía Manuel Velasco (INNN)

³ Neuroradiology, Universidad Nacional Autónoma de México, Instituto Nacional de Neurología y Neurocirugía Manuel Velasco (INNN)

Affiliations of all authors

^{1,2,3} Department of Endovascular Therapy, Universidad Nacional Autónoma de México, Instituto Nacional de Neurología y Neurocirugía Manuel Velasco (INNN)

Corresponding author: Cindy Díaz candru_diaz@hotmail.com,
cindydiaz@javeriana.edu.co

Phone: 5551829588

Conflicts of interest:

None

Intracranial Atherosclerotic Stenosis: An Up-to-Date Review

Cindy Díaz¹, Jorge Balderrama², Alba Herrera³, Alfredo Montenegro⁴

¹ Neurology, Endovascular Therapy Fellowship, Universidad Javeriana, Colombia, Universidad Nacional Autónoma de México, Instituto Nacional de Neurología y Neurocirugía Manuel Velasco (INNN)

^{2,4} Neuroradiology, Endovascular Therapy, Universidad Nacional Autónoma de México, Instituto Nacional de Neurología y Neurocirugía Manuel Velasco (INNN)

³ Neuroradiology, Universidad Nacional Autónoma de México, Instituto Nacional de Neurología y Neurocirugía Manuel Velasco (INNN)

Affiliations of all authors

^{1,2,3} Department of Endovascular Therapy, Universidad Nacional Autónoma de México, Instituto Nacional de Neurología y Neurocirugía Manuel Velasco (INNN)

Corresponding author: Cindy Díaz candru_diaz@hotmail.com, cindydiaz@javeriana.edu.co

Phone: 5551829588

Conflicts of interest:

None

1
2
3
4
5
6
7
8
9
10
11
12
13
14
15
16
17
18
19
20
21
22
23
24
25
26
27
28
29
30
31
32
33
34
35
36
37
38
39
40
41
42
43
44
45
46
47
48
49
50
51
52
53
54
55
56
57
58
59
60
61
62
63
64
65

Number of words: 7900

Figures: 3

References: 1

Intracranial Atherosclerotic Stenosis: An Up-to-Date Review

ICAD: intracranial atherosclerotic disease

CVA: cerebrovascular accident

IS: ischemic stroke

TIA: transient ischemic attack

TCD: transcranial doppler

MCA: middle cerebral artery

MRA: magnetic resonance angiography

A-ICAS: asymptomatic intracranial atherosclerotic stenosis

S-ICAS: symptomatic intracranial atherosclerotic stenosis

CTA: computerized tomography angiography

DSA: digital subtraction angiography

HRMRI: high-resolution magnetic resonance imaging

ICA: internal carotid artery

AMT: aggressive medical treatment

1
2
3
4 PTAS: percutaneous transluminal angioplasty and stenting
5
6

7
8 PTA: percutaneous transluminal angioplasty
9

10
11 ICH: intracerebral hemorrhage
12
13

14
15 ACA: anterior cerebral artery
16
17

18
19 PCA: posterior cerebral artery
20
21

22
23 EICS: elective intracranial stenting
24
25
26
27
28
29
30
31
32
33
34
35
36
37
38
39
40
41
42
43
44
45
46
47
48
49
50
51
52
53
54
55
56
57
58
59
60
61
62
63
64
65

INTRODUCTION

Cerebrovascular accidents (CVA) or strokes are one of the main mortality and morbidity causes around the world. Large-vessel atherosclerosis represents 20% of ischemic strokes (IS), 50% are intracranial, and it is associated with a high risk of recurrent CVA compared with other CVA subtypes, despite even the best medical care (1). Intracranial atherosclerotic disease (ICAD) is one of the main causes of IS, representing almost 5-10% of intracranial atherosclerotic strokes in the USA, and up to 50% in Asia (2).

In this review, we discuss recent clinical assays that have contributed to understanding the disease process associated with ICAD, risk factors associated with CVA recurrence in this subgroup of patients, imaging characteristics related to the prognosis, and an update on the treatments that reduce CVA recurrence.

EPIDEMIOLOGY

ICAD causes between 5 and 10% of IS in white people, between 20 and 30% of transient ischemic attacks (TIA) or CVA in black people, and up to 30 to 50% of CVA in Asian people (3)(4). From a total of 900,000 CVA or TIA that occur each year in the USA, approximately 70,000-90,000 are caused by intracranial atherosclerotic stenosis (3)(5). The risk of recurrent CVA in these patients could be as high as 15% per year (6)(7), and on other studies in patients with high-grade S-ICAD (stenosis: 70-99%), up to 23% per year despite aggressive antithrombotic therapy and standard vascular risk factor management (8)(9). Due to this elevated recurrence rate, there are alternative therapeutic options for the prevention of recurrent CVA in patients with severe ICAD that do not respond to medical treatments such as balloon angioplasty or stent placement (9)(10).

RISK FACTORS

Symptomatic and asymptomatic ICAD risk factors include:

-Age

-Race: Afro American, Hispanic, and Asian compared to white people. (4)(11).

-Cardiovascular risk pathologies:

*High blood pressure: In the Warfarin Aspirin Symptomatic Intracranial Disease (WASID) study, the most important modifiable risk factor that increases the risk of recurrent CVA and cardiovascular events (acute myocardial infarction and vascular death) associated with ICAD is high blood pressure (Systolic arterial pressure ≥ 140 mm Hg, HR= 1.79, p = 0.0009) (12).

*Diabetes Mellitus: High levels of A1C hemoglobin are not correlated to the severity of the ICAD, but diabetes mellitus remains as an independent risk factor (13).

*Hyperlipidemia: Those that are associated to a higher risk of recurrent CVA and ICAD progression are: total cholesterol serum levels ≥ 200 mg/dl (WASID study: Warfarin Aspirin Symptomatic Intracranial Disease, HR= 1.44, p = 0.048) (5)(12), increase in the apolipoprotein B (apoB)/apolipoprotein A-I (apoAI) rate (TOSS-2 study: Trial of cilostazol in Symptomatic intracranial Stenosis 2), decrease in serum levels of high-density lipoprotein cholesterol- HDL (14).

*Metabolic syndrome (15)(16).

-Sedentary lifestyle

-Smoking (17).

-Morphological characteristics of the stenosis: The risk of CVA in the territory of the stenotic artery was higher in severe stenosis $\geq 70\%$ (HR= 2.03, p = 0.0025) (18).

-Collateral circulation: The presence of good collaterality in patients with stenosis $\geq 70\%$ decreases the risk of recurrent CVA, making the extension of collaterality a predicting factor of CVA in asymptomatic arterial territory (HR= 4.36, p = 0.0001) (19). Collateral circulation is a potent determinant of the risk of CVA in ICAD, evidencing a protective role with severe stenoses and identifying more unstable minor stenoses (50-69%).

BIOMARKERS

Other biomarkers associated with a higher risk of recurrent CVA or ICAD progression are (20)(21)(22):

-Reduction: adiponectin

-Increase: phospholipase-A2 associated with Lipoprotein-Associated Phospholipase A(2) (Lp-PLA2), C-reactive protein (CRP), Plasminogen activator inhibitor-1 (PAI-1), and lipoprotein (A).

PHYSIOPATHOLOGY OF CVA IN ICAD

The three main physiopathological mechanisms of ICAD-related CVA include (23):

1. Hemodynamic: Distal hypoperfusion (ischaemic infarcts in a watershed distribution on brain imaging)
2. Embolic: artery-artery (distal wedge-shaped territorial infarct or multiple cortical infarcts on brain imaging)
3. Branch atheromatous disease: extension of the atherosclerotic plaque to the ostium of small perforating arteries (lacunar infarctions on brain imaging)

These CVA mechanisms in the ICAD context can happen in isolation or combined, Caplan and Hennerici (24)(25) suggested interrelated and complementary occurrences of hypoperfusion and embolia, stating that the decrease of distal arterial perfusion to high grade stenosis limits the capability of the embolus formed in the stenotic atherosclerotic area to be washed out of cerebral circulation, and thus, lead to accumulation in the regions of less perfusion pressure, i.e., in the areas of terminal supply and border zone areas (24).

The mechanism of initial CVA inicial in the context of ICAD is a predictor of the CVA subsequent physiopathological mechanism or the risk of recurrence. The risk of recurrent CVA in patients who presented a lacunar CVA in the WASID study was 18%, which is higher than expected of ICAD were an unrelated asymptomatic spectator (26), compared with the annual recurrence rate after a lacunar CVA in a population study that was 2% to 3%.

Some studies have evaluated the correlation between the CVA pattern (hemodynamic, artery-artery embolic, or branch or performing vessel atheromatous disease) with CVA recurrence rates in relation to anatomy, distribution, and the presentation of

1
2
3
4 underlying stenosis. As such, basilar artery stenosis has more probability of presenting as a
5
6 performing vessel CVA, and less probability of recurring. Patients with suboptimal medical
7
8 treatments have double the probability of suffering a recurrent CVA. Among patients with
9
10 optimal medical treatment, no recurrent CVAs were observed with an embolic artery-artery
11
12 pattern, while there was a recurrence rate of 57% in patients with a watershed infarct pattern.
13
14 We suggest that CVA due to ICAD with a hemodynamic mechanism could respond less to
15
16 medical therapy, while ICAD caused by the destabilization of the plaque or in perforating
17
18 territories could benefit from aggressive medical therapy and late or step by step
19
20 endovascular treatment (27).
21
22
23
24
25
26

27
28 Some patients with ICAD present a lacunar type CVA fairly close to the ICAD, which
29
30 poses the question of whether the infarction is caused by the stenosis or if it is a result of a
31
32 small perforating vessel disease coexisting with asymptomatic ICAD. In the latter, a low risk
33
34 of recurrent CVA in the territory of the stenotic artery could be expected, while for the
35
36 former, a higher risk could be expected. The distinction between these two scenarios could
37
38 be relevant to characterize the physiopathology, and more importantly, to determine the
39
40 prognosis and treatment (28)(29).
41
42
43
44

45
46 Khan et al (29) assessed the probability of a lacunar CVA lacunar vs a recurrent non-
47
48 lacunar posterior to a first lacunar CVA secondary to ICAD, and they concluded that in
49
50 patients with symptomatic ICAD (S-ICAD), the risk of recurrent CVA was similar among
51
52 patients who started with lacunar or non-lacunar CVA (recurrence risk with lacunar index
53
54 event 18% vs non-lacunar 22%, HR 0.79), and the recurrent CVA in patients who started with
55
56 lacunar CVA was typically non-lacunar and distal to the stenotic intracranial artery.
57
58
59
60
61
62
63
64
65

DIAGNOSIS: THE ROLE OF IMAGING

Diagnostic tools used to identify ICAD include:

Non-invasive methods:

- Transcranial Doppler (TCD): It is superior when providing flow information in real time and evidencing the direction of flow, collaterality, embolization (microembolic signs are an independent predictor of recurrence of CVA in patients with S-ICAD), and steal phenomenon, compared with static CT and MRA images (30). It is useful for the standardized exploration protocol of Stroke Outcomes and Neuroimaging of Intracranial Atherosclerosis (SONIA) criteria to identify stenosis $\geq 50\%$ stenosis. The optimal combined criteria for stenosis $\geq 70\%$ were MCA average velocity >120 cm/s, or a stenosis/pre-stenosis ratio ≥ 3 , or average-low velocity. In vertebral artery/basilar artery it varies >110 cm/s or stenotic/prestenotic ratio ≥ 3 (31).

- Magnetic resonance angiography (MRA): TOF-MRA is a flow sequence, accentuating hemodynamic characteristics and, as such, it generally overestimates the grade of stenosis, especially in cases with low distal flow to the ICAD location. The advantage of this sequence is that it makes it possible to evaluate the hemodynamic impact of the lesion (32).

Measurement techniques like the WASID Measurement Technique have been developed. Two measurements for each intracranial ACI are taken: 1) a linear measurement at the location of the most severe stenosis in the images either the MIP or axial source images; and 2) a linear measurement of the widest normal, non-tortuous portion of the petrous ACI parallel to the location of the stenosis. Using these measurements, we calculated the WASID

grade of stenosis using the following equation: Percentage of stenosis = $[(1 - [D \text{ stenosis} / D \text{ normal}])] \times 100$, where D stenosis is the diameter of the artery at the location with the most severe grade of stenosis and D normal is the diameter of the proximal artery in its widest, non-tortuous normal segment (33).

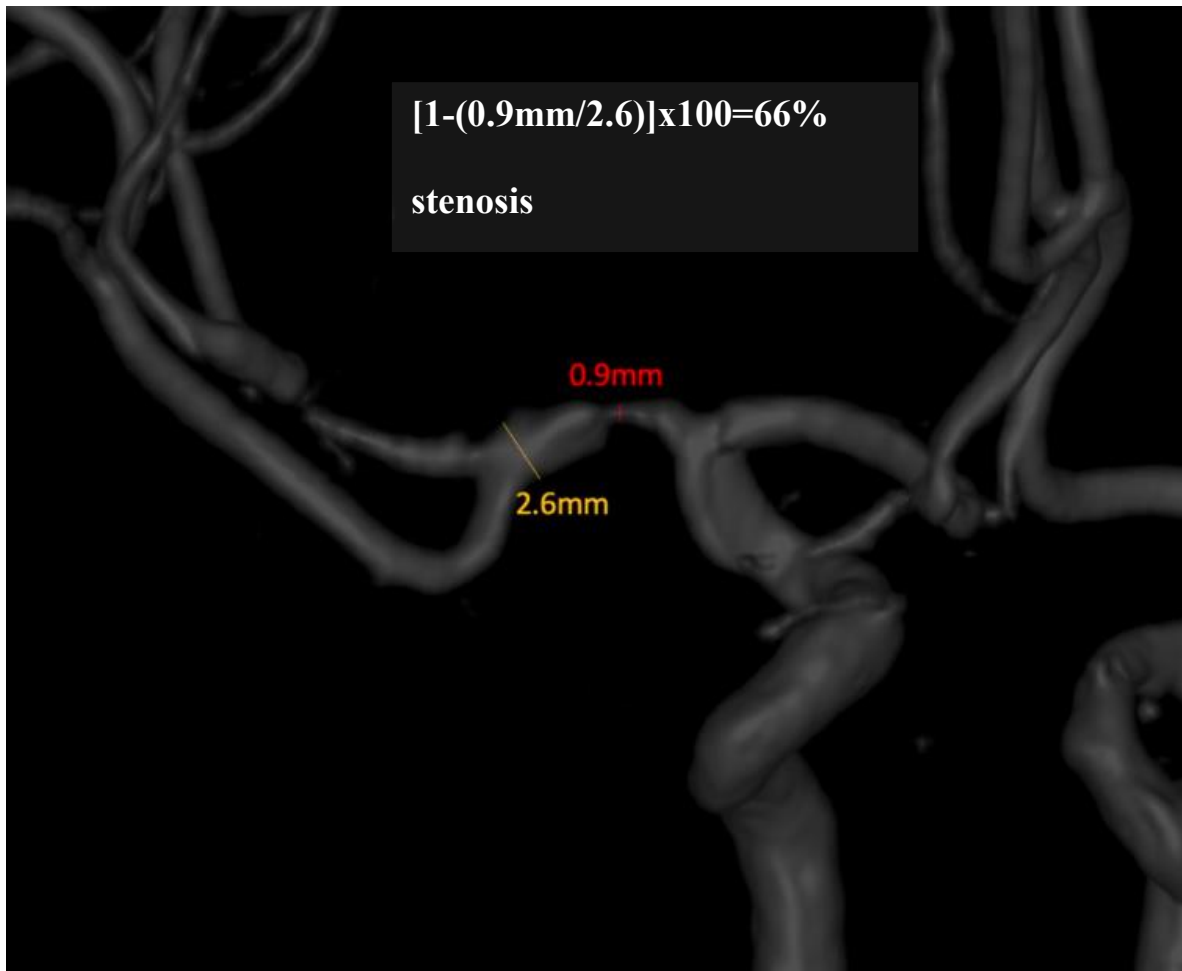


Figure 1. WASID Measurement Technique: MRA MIP images demonstrating high-grade stenosis of the right intracranial MCA. For an accurate measurement of the grade of Warfarin-Aspirin Symptomatic Intracranial Disease Stenosis, we made a linear measurement of the most stenotic portion of the MCA, in this case 0.9 mm. A second “normal” measurement was made at the widest, non-tortuous, normal portion of the MCA that had

1
2
3
4 margins parallel with the location of the stenosis, in this case 2.6 mm. The ratio of these two
5
6 measurements was then used to calculate the WASID stenosis, in this case $[1-(0.9$
7
8 $\text{mm}/2.6)] \times 100 = 66\%$ stenosis.
9

10
11
12 - Computerized tomography angiography (CTA): It provides a better delimitation of the
13
14 anatomy of intracranial arteries, which allows for higher diagnostic precision of luminal
15
16 stenosis in ICAD compared to the TCD and MRA, with a sensitivity >95% in the diagnosis
17
18 of ICAD (34) using DSA as the reference standard, even though the visualization of petrous
19
20 and the cavernous segments of the internal carotid artery (ICA) by CTA could be affected by
21
22 bone artifacts. Recently, CTA has been used more and more to evaluate collaterality in ICAD,
23
24 including the leptomeningeal collaterals, which have been correlated to the risk or recurrent
25
26 events, and recurrent CVA rates have been reported in patients with high grade stenosis (70-
27
28 99%) of none vs good collaterality: HR= 4.60, and poor vs good collaterality: HR= 5.90
29
30 (35)(36). Consequently, collateral flow is one of the most essential mediators in cerebral
31
32 ischemia due to ICAD, making it an important indicator in the prediction of risk and the
33
34 assignment of treatment in patients with symptomatic ICAD.
35
36
37
38
39
40
41
42

43 The anterograde and collateral blood flow (AnCo) scoring system is useful as a score
44
45 to predict the state of anterograde and collateral blood flow in patients with S-ICAD of the
46
47 MCA. The AnCo scoring system consists of the anterograde score (AnS) and the collateral
48
49 score (CoS) (37).
50
51
52
53

54 Bash et al, after analyzing 115 sick vessels, found that CTA has higher sensitivity
55
56 than MRA to detect ICAD (98% vs 70%, $p < 0.001$), and occlusion (100% vs 87%, $p = 0.02$).
57
58 CTA had a positive predictive value higher than MRA, both for stenosis and occlusion. CTA
59
60
61
62
63
64
65

was superior to DSA in the detection of the permeability of the vessel. In conclusion, CTA has higher sensitivity and positive predictive value than MRA and is recommended over the TOF sequence of the MRA to detect intracranial stenosis and occlusion. CTA is superior to DSA to assess steno-occlusive disease of posterior circulation when there is slow flow (34). In another study that compared DSA and CTA, they found that CTA has high sensitivity and specificity to detect stenosis $\geq 50\%$ in large intracranial segments (38).

-High-resolution magnetic resonance (HRMRI): It help in the assessment of the morphology of the intracranial plaque and the adjacent arterial wall, revealing the morphology and components of the plaque, including intraplaque, lipidic nucleus, and fibrous layer hemorrhage (36).

-Perfusion images (PerfuMRI or PerfuCT): this imaging modality makes it possible to identify potentially recoverable tissue or ischemic penumbra, so that they could be used to quantify the real collateral flow in the context of ICAD (39).

Invasive methods:

-Digital subtraction angiography (DSA): It is currently considered as the reference standard for the diagnosis of intracranial vascular diseases, including ICAD, because of its excellent spatial and contrast resolution to represent the vessels, and its capability to reveal temporal information about anterograde and collateral flow. A disadvantage as an invasive method is that it may lead to complications during the procedure, with rates of 1:1000 general neurological complications being reported (close to 2% in patients with ICAD) (32). Therefore, DSA should not be routinely used to diagnose ICAD.

1
2
3
4 A challenge posed by these diagnostic tests is their limited capability to differentiate
5
6 between an atherosclerotic plaque and other pathologies such as partially occlusive thrombus,
7
8 vasospasm, vasculitis, or even preocclusive Moyamoya disease. Lately, high-resolution
9
10 images of the vessel wall have been used to identify substenotic but active atherosclerotic
11
12 plaques. In patients with ICAD, eccentric arterial thickening, and fibrous cap thickening in
13
14 the image of the vessel wall could favor atherosclerosis of the thrombus or vasculitis (40).
15
16
17
18
19

20 The SONIA (Stroke Outcomes and Neuroimaging of Intracranial Atherosclerosis)
21
22 study assessed the precision TCD and MRA compared to DSA, and it concluded that both
23
24 have high negative predictive values (86 and 91%, respectively), but low positive predictive
25
26 values (36 and 59%, respectively). Both techniques identify 50 to 99% of stenoses of large
27
28 intracranial vessels non-invasively with substantial negative predictive value. This means
29
30 that TCD and MRA are efficient for the exclusion of ICAD, but are less useful to establish a
31
32 diagnosis of ICAD and to estimate the severity of the stenosis. Additionally, abnormal
33
34 findings in TCD and MRA require a confirmation test, such as DSA, to reliably identify
35
36 stenosis (30).
37
38
39
40
41
42

43 DSA is the diagnostic test that more precisely measures the grade or percentage of
44
45 intracranial stenosis, above non-invasive tests. In conclusion, DSA is the gold standard for
46
47 diagnosis and quantification of luminal stenosis of intracranial circulation, which is an
48
49 independent predictor of recurrent CVA in the context of ICAD (41). However, the grade of
50
51 stenosis is not the only determining factor. Other factors are collateral circulation
52
53 (hemodynamic impact), and morphological characteristics of the atherosclerotic plaque
54
55 (plaque components) (32).
56
57
58
59
60
61
62
63
64
65

TREATMENT

There are three types of treatment for ICAD: Medical, endovascular, and surgical treatment.

Medical treatment

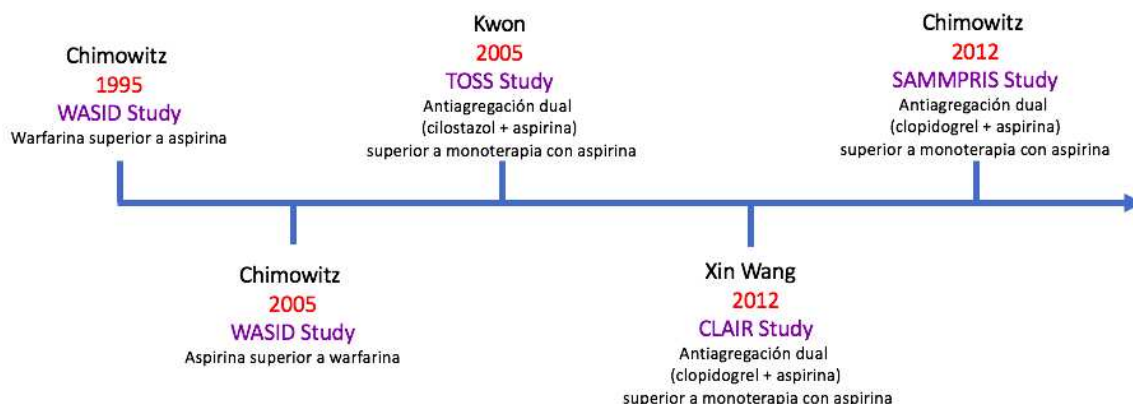


Figure 2: Timeline for pharmacological treatment in patients with ICAD.

In 1995, Chimowitz et al (Warfarin-Aspirin Symptomatic Intracranial Disease Study Group: WASID) published the multicentric and retrospective study: the “Warfarin-Aspirin Symptomatic Intracranial Disease Study”, to compare the efficacy of warfarin vs aspirin in the prevention of major vascular events (CVA, AMI or sudden death) in patients with S-ICAD. Seven centers and 151 patients participated; 88 were treated with warfarin and 63 with aspirin. The follow-up median was 14.7 months (warfarin group), and 19.3 months (aspirin group). Kaplan-Meier analysis showed a significantly higher percentage of patients free of major vascular events among patients treated with warfarin ($p = 0,01$). The relative risk of an important vascular event for these patients was 0.46 (95%CI: 0.23-0.86) as opposed

1
2
3
4 to patients treated with aspirin. Important hemorrhagic complications occurred in three
5
6 patients treated with warfarin (including two deaths) in 166 patients-year of follow-up, and
7
8 none in the patients treated with aspirin in 143 patients-year of follow-up. This study suggests
9
10 a favorable risk-benefit relation for warfarin, compared to aspirin for the prevention of major
11
12 CVA in patients with S-ICAD (42). This resulted in anticoagulation being informed for the
13
14 first time as treatment for S-ICAD.
15
16
17
18
19

20 Later on in 2005, Chimowitz et al (Warfarin-Aspirin Symptomatic Intracranial
21
22 Disease Study Group: WASID) published the multicentric blind clinical trial: “Comparison
23
24 of Warfarin and Aspirin for Symptomatic Intracranial Arterial Stenosis”, where they
25
26 randomized patients with these inclusion criteria: age ≥ 40 years, non-incapacitating TIA or
27
28 CVA occurring 90 days before randomization, and which was attributable to a 50-99%
29
30 stenosis verified by DSA in a main intracranial artery, a modified Rankin score ≤ 3 , in two
31
32 groups: warfarin 5 mg per day (INR objective 2.0-3.0) vs aspirin (total dosis per day: 1300
33
34 mg, 650 mg every 12 hours). In total, 569 patients were randomized, the study was stopped
35
36 because of the worry regarding the safety profile of the arm of patients assigned to warfarin.
37
38 During an average follow-up period of 1.8 years. The death ratio due to vascular causes was
39
40 3.2% aspirin vs 5.9% warfarin ($p = 0.16$); the death ratio due to non-vascular causes was
41
42 1.1% vs 3.8%, respectively ($p = 0.05$). In conclusion, warfarin was associated with
43
44 significantly higher rates of adverse effects and did not provide any benefits compared to
45
46 aspirin in this study. Aspirin should be preferably used instead of warfarin in patients with
47
48 ICAD. A subanalysis was performed in the following contexts: severe stenosis (70-99%),
49
50 vertebrobasilar stenosis or CVA symptoms in patients with antithrombotic treatment
51
52 (therapeutic failure or failure in the response), who were previously thought to be benefitting
53
54
55
56
57
58
59
60
61
62
63
64
65

1
2
3
4 from anticoagulation therapy. However, the WASID study findings showed that none of
5
6 these subgroups have a significant benefit with warfarin (5).
7
8
9

10 In 2009, Turan et al published “Failure of Antithrombotic Therapy and Risk of Stroke
11
12 in Patients With Symptomatic Intracranial Stenosis”, where they compared CVA or vascular
13
14 death rates in ON vs OFF patients (patients in antithrombotic treatment or warfarin at the
15
16 time when the index event occurred to be included in the WASID study vs patients without
17
18 treatment). Concluding, patients with S-ICAD who fail in antithrombotic therapy do not
19
20 have a higher risk of CVA than those that do not fail with this therapy. Given the fact that
21
22 patients with antithrombotic treatment ON and OFF have a higher risk of CVA in the
23
24 territory, the intracranial stent placement assays should not be limited to only those who fail
25
26 in this therapy (43).
27
28
29
30
31
32

33 In 2012, Xin Wang et al, published “The effectiveness of dual antiplatelet treatment
34
35 in acute ischemic stroke patients with intracranial arterial stenosis: a subgroup analysis of
36
37 CLAIR study”, where they carried out an analysis of subgroups of the CLAIR study in
38
39 patients with CVA or TIA with ICAD and microembolic signs confirmed with TCD recorded
40
41 on days 1, 2, and 7. They included patients during the first seven days after the onset of
42
43 symptoms, randomizing in two groups: group 1, clopidogrel (day 1: 300 mg and subsequently
44
45 75 mg/day plus aspirin (75-160 mg/day) for seven days (dual treatment), or just aspirin (75-
46
47 160 mg/day) for seven days (monotherapy). They included 70 patients, 34 in the dual
48
49 treatment dual and 36 in the monotherapy group. To conclude, dual treatment with
50
51 clopidogrel and aspirin for seven days is more effective than only aspirin for reducing
52
53 microembolic signs in patients with S-ICAD (44).
54
55
56
57
58
59
60
61
62
63
64
65

1
2
3
4 In 2012, the “Stenting versus Aggressive Medical Therapy for Intracranial Arterial
5 Stenosis, SAMMPRIS Trial Investigators” was published, supporting the use of dual
6 antithrombotic in the short term with aspirin and clopidogrel, followed by just aspirin. In this
7 study they compared the aggressive medical treatment (AMT) vs percutaneous transluminal
8 angioplasty and stenting (PTAS) to prevent recurrent CVA. The AMT in the SAMMPRIS
9 study included:
10
11
12
13
14
15
16
17

18
19
20 -Dual antithrombotic therapy: aspirin 325 mg/day + clopidogrel 75 mg/day for 90 days after
21 enrollment and subsequently, aspirin 325 mg/day during the rest of the assay.
22
23
24

25
26 -Control of primary risk factors: blood pressure <140/90 mm Hg (<130/80 mm Hg in case of
27 patients with diabetes) and cholesterol levels LDL < 70 mg/dl.
28
29
30

31
32 -Control of secondary risk factors: diabetes mellitus, elevated non-high-density lipoprotein
33 (non-HDL) cholesterol, smoking, obesity, and sedentarism aided by a lifestyle modification
34 program.
35
36
37
38
39
40

41 The common practice of keeping blood pressure slightly high in patients with S-
42 ICAD to reduce the risk of CVA by distal hypoperfusion, and increasing the systolic arterial
43 pressure during follow-up in WASID did not reduce the risk of CVA in the stenotic artery
44 territory, but in fact it increased the risk of recurrent CVA.
45
46
47
48
49
50

51 Patients who had had a recent (30 days) TIA or CVA attributed to 70-99% stenosis
52 of the diameter of a major intracranial artery with AMT or AMT plus PTAS with a Wingspan
53 stent were randomly assigned. The primary outcome was CVA or death within the following
54 30 days after enrollment or after a revascularization procedure for the qualifying lesion
55
56
57
58
59
60
61
62
63
64
65

1 during the follow-up period or the CVA in the territory of the qualifying artery after the 30
2 days. The study stopped at the beginning of 2011, regardless of the fact that follow-up will
3
4
5
6
7
8
9 finish in 2013. In total, 451 were randomized, because the rate of CVA or death at 30 days
10
11 was 14.7% in the PTAS group (12.5% non-fatal CVA and 2.2% fatal CVA), and 5.8% in the
12
13 medical treatment group (5.3% non-fatal CVA and 0.4% death unrelated to CVA) $p = 0.002$.
14
15 The average duration of follow-up was 11.9 months. The probability of a primary outcome
16
17 over time significantly differed between the two treatment groups ($p = 0.009$), with a one-
18
19 year rate of 20.0% primary outcome in the PTAS group, and 12.2% in the AMT group (8).
20
21
22
23
24

25 The patients in the AMT group only had a 5.8% CVA or death rate at 30 days, which
26
27 is substantially lower than 10.7% at 30 days in the WASID assay (using the same inclusion
28
29 criteria as SAMMPRIS).
30
31
32

33 Other antiplatelet agents like cilostazol, a phosphodiesterase inhibitor, in dual therapy
34
35 (aspirin 100 mg/day + cilostazol 200 mg/day) have been tested in the TOSS (Trial of
36
37 cilostazol in Symptomatic intracranial arterial Stenosis) study (45). No data on the superiority
38
39 or equivalence of other antiplatelet regimes such as monotherapy with clopidogrel, cilostazol
40
41 or extended release dipyridamole, or the combination of dipyridamole and aspirin has been
42
43 published for the prevention of CVA in patients with S-ICAD.
44
45
46
47
48
49
50
51
52

53 Endovascular treatment
54
55
56
57
58
59
60
61
62
63
64
65

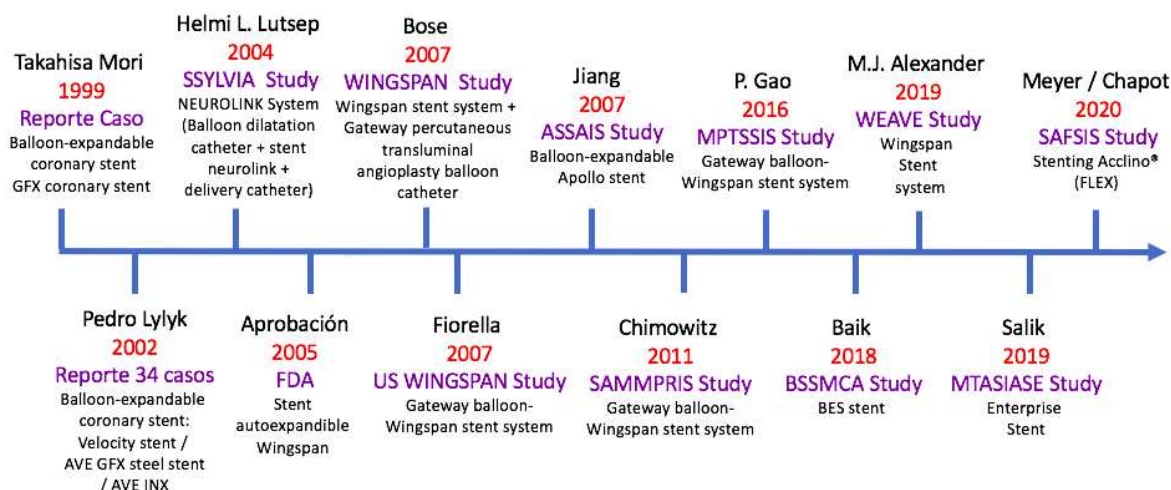


Figure 3. Endovascular treatment timeline in patients with S-ICAD.

Reports in 1999 and 2002, which involve a small number of patients with ICAD that were treated with coronary angioplasty catheters or balloon-expandable stents showed promising results (46)(47). Nevertheless, the safety of these procedures could have been compromised by these factors: 1) flexibility limitations of the coronary balloons or the placement systems of balloon-mounted stents; 2) high inflation precision required to deploy stainless steel stents in fragile intracranial vessels; 3) risk of shearing the stent from the balloon while navigating to the target lesion; and 4) difficulty to precisely dimension the balloons and endoprotheses according to the diameter of the vessel (48).

In 2004, the SSYLVA Study Investigators, published the a prospective, multicentric and non-randomized study: “Stenting of Symptomatic Atherosclerotic Lesions in the Vertebral or Intracranial Arteries (SSYLVA) Study Results”, which evaluated the NEUROLINK system (Boston Scientific, Natick, Mass), comprising a balloon dilatation catheter and a stainless steel stent. They included patients between 18 and 80 years, with symptoms attributable to target lesions with $\geq 50\%$ stenosis. They recruited 61 patients, with

95% success rate of the procedure. During the first 30 days, four patients (6.6%) suffered a CVA and no deaths occurred. At six months, a $> 50\%$ stenosis occurred in 32.4%, and from these patients, the recurrent stenosis was symptomatic in 39% of them. In conclusion, the NEUROLINK system is associated with a high rate of successful deployment in the endoprosthesis. CVA occurred in 6.6% of patients within 30 days, and 7.3% between day 30 and one year. Even though stenoses occurred in 35% of patients, 61% were asymptomatic(49).

In 2005, the FDA approved the Wingspan (Stryker Neurovascular, Freemont, CA, EE. UU.) self-expanding stent for use under the exception of the humanitarian device in medically-refractory patients with TIA or CVA secondary to 50-99% stenosis of a major intracranial artery.

In 2007, Bose et al published “A Novel, Self-Expanding, Nitinol Stent in Medically Refractory Intracranial Atherosclerotic Stenoses The WINGSPAN Study”, which was a prospective, multicentric study with just one arm. They evaluated the safety and performance of the Wingspan stent system and the slow-inflation nominal pressure undersized balloon catheter PTA - Gateway in the treatment of high-grade S-ICAD in patient who had not responded to medical treatment. The inclusion criteria were: refractory patients to AMT, modified Rankin score ≤ 3 , and recurrent symptoms attributable to intracranial stenosis seen angiographically $\geq 50\%$ in a 2.5 to 4.5 mm diameter vessel. They included 45 patients, the stenosis grade was reduced from an initial value of $74.9 \pm 9.8\%$ to $31.9 \pm 13.6\%$ after the placement of the stent and to $28 \pm 23.2\%$ at the six-month follow-up. The combined death/ipsilateral CVA at 30 days was 4.5%, and during the six-month follow-up, the CVA/ipsilateral death rate 7.0%, the rate for all CVA was 9.7%, and mortality due to all causes

1
2
3
4 was 2.3%. To summarize, in medically refractory patients with high-grade S-ICAD, a new
5
6 treatment paradigm that involves pre-dilation with an undersized balloon catheter for PTA
7
8 Gateway followed by the deployment of the self-expanding Wingspan stent endoprosthesis
9
10 to remodel the target vessel even further and maintain the permeability without the need for
11
12 post-dilation seems to be safe, may facilitate the remodeling, and may contribute to favorable
13
14 angiographic results (48).
15
16
17
18
19

20 Subsequently, the results of two multicentric studies in the USA were recorded. Based
21
22 on the reports of the WASID study that showed that patients with high-grade S-ICAD (70%
23
24 - 99%) have a particularly high risk of ipsilateral CVA even with AMT: 18% per year. Thus,
25
26 the following two multicentric studies to evaluate the effectiveness and safety of
27
28 endovascular treatment are shown.
29
30
31
32

33 In 2007, Fiorella et al publish “US Multicenter Experience With the Wingspan Stent
34
35 System for the Treatment of Intracranial Atheromatous Disease Periprocedural Result”, a
36
37 study that informed the initial periprocedural experience with Wingspan (Boston Scientific
38
39 / Target), the first self-expanding stent system designed for ICAD treatment. All patients
40
41 underwent angioplasty and stent placement using the Gateway balloon–Wingspan stent
42
43 system. During a period of nine months, the treatment with the stent system was performed
44
45 on 78 patients (average age: 63 years) with 82 atheromatous intracranial lesions, from which
46
47 54 had $\geq 70\%$ stenosis. The success rate for this procedure was 98.8% during the first
48
49 treatment session. In one case, the stent could not be placed through the lesion. Average
50
51 stenosis pre-treatment was $74.6 \pm 13.9\%$, improving to $43.5 \pm 18.1\%$ after balloon
52
53 angioplasty, and to $27.2 \pm 16.7\%$ after the placement of the endoprosthesis. Out of the 82
54
55 treated lesions, there were five (6.1%) important neurological complications during the
56
57
58
59
60
61
62
63
64
65

1
2
3
4 procedure, from which four finally led to the death of the patient within 30 days of treatment.
5
6 In conclusion, angioplasty and endoprosthesis placement for S-ICAD could be carried out
7
8 with the Gateway balloon–Wingspan stent system with a high rate of technical success and
9
10 an acceptable periprocedural morbidity. This procedure is considered a viable treatment
11
12 option for these patients (50).
13
14

15
16
17 In 2007, Jiang et al published “Apollo Stent for Symptomatic Atherosclerotic
18
19 Intracranial Stenosis: Study Results”, a prospective study that evaluated the viability and
20
21 results of a new intracranial balloon-expandable Apollo stent (MicroPort Medical
22
23 [Shanghai], Shanghai, China) that comprises a semi-compliant balloon, a stent, and a delivery
24
25 catheter. They recruited 46 patients with $\geq 50\%$ stenosis. The viability of the procedure was
26
27 assessed through the success of the stent (residual stenosis $\leq 30\%$) and procedure length. The
28
29 primary final outcome was CVA in the territory of the target lesion artery, including any
30
31 CVA and death within 30 days. In total, 91.7% were successful with the stent with an average
32
33 procedure time of 50.6 minutes. Three patients (6.5%) suffered minor CVA within 30 days.
34
35 All patients were available for follow-up with a mean of 23.9 months. After 30 days, one
36
37 patient (2.2%) developed a mild CVA in the territory of the target lesion in the artery after
38
39 6.7 months. The primary outcome rate was 4.3 per 100 patients-year. Angiographic follow-
40
41 up was done for 25 patients. They detected seven restenosis (28%), one of which was
42
43 symptomatic. Concluding, an angioplasty with the Apollo stent for S-ICAD is feasible.
44
45 Severe tortuosity is an independent predictor of stent failure. Our clinical results seem to be
46
47 favorably comparable to the results of aspirin therapy (51).
48
49
50
51
52
53
54
55
56
57

58 In 2008, Zaidat et al published “The NIH registry on use of the Wingspan stent for
59
60 symptomatic 70–99% intracranial arterial stenosis”, a multicentric study where 16 centers
61
62
63
64
65

1 participated. They recruited a total of 129 patients with severe S-ICAD (70 - 99%). The
2
3
4
5
6 technical success rate was 96.7%. The average stenosis pre- and post-stent were 82% and
7
8
9 20%, respectively. The frequency of any CVA, intracerebral hemorrhage (ICH) or death
10
11 within 30 days or ipsilateral CVA after 30 days was 14.0% at six months. The frequency of
12
13 restenosis $\geq 50\%$ in the follow-up angiography was 25%. To conclude, the use of a Wingspan
14
15 stent in patients with severe S-ICAD (70-90%) is relatively safe with a high technical success
16
17 rate and a moderately high rate of restenosis. The comparison of event rates in high-risk
18
19 patients in symptomatic warfarin and aspirin intracranial disease (WASID) against this
20
21 registry, does not discard that the stent placement could be associated with a substantial
22
23 reduction of the relative risk (e.g, 50%) or that it does not have any advantage compared to
24
25 medical therapy. A randomized assay that compares stent placement and medical therapy is
26
27 required (52).
28
29
30
31
32
33

34
35 As stated previously, the SAMMPRIS assay that started enrollment in 2008, had
36
37 opposite results in relation to the researchers hypothesis, evidencing that AMT was superior
38
39 to PTAS in high-risk S-ICAD patients (8). An analysis in 2012 was done by Fiorella et al,
40
41 who found that the risk factors that were significantly associated with periprocedural
42
43 ischemic events in the SAMMPRIS study were: not smoking (possibly because smoking
44
45 increases the clopidogrel conversion into its active metabolite), basilar artery stenosis,
46
47 diabetes, and advanced age, while risk factors associated with periprocedural ICH included
48
49 high percentage of stenosis and clopidogrel load associated with a coagulation time above
50
51 the target range (53).
52
53
54
55
56
57

58 The explanations for the highest periprocedural events in SAMMPRIS compared to
59
60 previous Wingspan reports are: more severity of the necessary stenosis for the enrollment in
61
62
63
64
65

1
2
3
4 SAMMPRIS, and previous treatment in SAMMPRIS (within the 30 days after the qualifying
5 event), which could have increased the risk of PTAS. Besides, it had a more rigorous
6 adjudication procedure.
7
8
9

10
11
12 In 2016, P. Gao et al published “Multicenter Prospective Trial of Stent Placement in
13 Patients with Symptomatic High-Grade Intracranial Stenosis”, a prospective multicentric
14 assay in only one arm aiming at evaluating if the modifications in the selection of the patients
15 for stenting could lead to lower rates of CVA or periprocedural death. They included patients
16 with recent TIA or CVA (excluding performing vessel CVA) related to high grade stenosis
17 (70 -99%) of a main intracranial artery. They were treated by angioplasty and self-extending
18 stents three weeks after the index ischemic event. The endovascular technique used the
19 Gateway angioplasty balloon (Stryker Neurovascular). After the angioplasty, the Gateway
20 angioplasty balloon catheter, self-expanding nitinol Wingspan stent delivery system. They
21 recorded 100 patients, target lesions were located more frequently in the M1 segment of the
22 MCA (38. 3%), intracranial ICA (17.17%), intradural vertebral artery (18.18%), and basilar
23 artery (27.27%). The technical success rate of the deployment of the endoprosthesis with <
24 50% residual stenosis was 100%. The global rate of CVA and/or death at one month was 2%.
25 Two CVA occurred in the pons region (distribution of performing vessels) in patients after
26 angioplasty a stent placement by stenosis of the basilar artery. Concluding, they evidenced
27 that the modifications in patient selection and the aspects of the procedure could greatly
28 reduce the rate of CVA and/or death a month after the placement of the intracranial stent
29 (41).
30
31
32
33
34
35
36
37
38
39
40
41
42
43
44
45
46
47
48
49
50
51
52
53
54
55
56
57

58 In 2018, Baik et al published “Balloon-expandable stents for treatment of
59 symptomatic middle cerebral artery stenosis: Clinical outcomes during long-term follow-up”,
60
61
62
63
64
65

1
2
3
4 where they retrospectively reviewed the clinical results during long-term follow-up after the
5
6 insertion of expandable balloon stents in patients with MCA S-ICAD. They analyzed 34
7
8 patients, with an average age of 67 years with MCA S-ICAD. They used the BES stent
9
10 (Flexmater; Abbott, Abbott Park, MI, USA) that was sized to approximate the diameter of
11
12 the normal patent vessel. During the follow-up period after the placement, which varied
13
14 between 61 and 108 months (median of 67.5 months), TIA occurred in five patients, from
15
16 which one experienced complete reocclusion of the MCA stent and three had symptomatic
17
18 restenosis. The remaining 29 patients did not experience more ischemic events or restenosis
19
20 during the follow-up period. In conclusion, treatment with expandable balloon stents in
21
22 patients with MCA S-ICAD resulted in low recurrence rates, both for ischemic events and
23
24 restenosis during long-term follow-up (7).
25
26
27
28
29
30
31

32 In 2019, Michael J. Alexander et al from WEAVE Trial Investigators published
33
34 “WEAVE (Wingspan Stent System Post Market Surveillance) Trial Final Results in 152 On-
35
36 Label Patients”, where they analyzed 152 patients who complied with the criteria for use
37
38 indicated in the FDA label (22-80 years of age, severe S-ICAD (70-99% stenosis), base
39
40 modified Rankin score ≤ 3 , ≥ 2 CVA in the vascular territory of the stenotic lesion with at
41
42 least one CVA during medical treatment and stent placement in the lesion ≥ 8 days after the
43
44 last CVA, in 24 hospitals. They underwent an angiography and stent placement using a
45
46 Wingspan stent (Stryker, Kalamazoo, MI). The assay stopped before completion after the
47
48 intermediate analysis of 152 consecutive patients evidenced CVA, ICH, and death rates
49
50 during the procedure lower than expected (2.6%) (4/152 patients). This was lower than the
51
52 4% safety reference of primary outcome established for the intermediate analysis in the study.
53
54 A total of 97.4% (148/152) of the patients were event-free at 72 hours, 1.3% (2/152) non-
55
56
57
58
59
60
61
62
63
64
65

1
2
3
4 fatal CVA, and 1.3% (2/152) patients died. In conclusion, experienced interventionists and
5
6 an adequate selection of the patients following the FDS label indications, the use of the
7
8 Wingspan stent for S-ICAD showed a low rate of periprocedural complications and an
9
10 excellent safety profile. This is the biggest multicentric prospective study on the Wingspan
11
12 stent system label up-to-date with the lowest reported complication rate (54).
13
14
15

16
17 In 2019, Salik et al published “Medium-term results of undersized angioplasty and
18
19 stenting for symptomatic high-grade intracranial atherosclerotic stenosis with Enterprise”, a
20
21 study which assessed the medium-term results of the undersized balloon angioplasty and
22
23 stenting for high grade S-ICAD (70-99%) of a main intracranial artery with an Enterprise
24
25 stent (Codman Neurovascular, Raynham, Massachusetts, USA), which was originally
26
27 designed for neck remodeling in the treatment of intracranial aneurysms. In total, 68 patients
28
29 with S-ICAD under AMT with high grade stenosis (70-99%) of a major intracranial artery
30
31 that were treated endovascularly with undersized balloon angioplasty and Enterprise stent
32
33 deployment. The primary outcome was CVA or death within 30 days of the procedure.
34
35 Secondary outcomes were technical success rates, CVA, and restenosis during the follow-up
36
37 period. The success rate for the procedure was 99%. The grade of stenosis prior to the
38
39 procedure was $92 \pm 6\%$, and it decreased to $12 \pm 10\%$ after the deployment of the stent. No
40
41 patients suffered CVA or death during the periprocedural period. ICH was observed in one
42
43 (1.5%) patient. In 60 (88%) patients with available imaging follow-up, they observed
44
45 restenosis in the stent in two patients. The average follow-up period was 22 ± 17 months
46
47 (range 6-72), and none of the patients experienced recurrent TIA or CVA during follow-up.
48
49 Concluding, undersized balloon angioplasty and deployment of a self-expanding stent with
50
51 a relatively low radial strength was safe and efficient for endovascular treatment of high
52
53
54
55
56
57
58
59
60
61
62
63
64
65

grade S-ICAD with high technical success rates, low periprocedural complication rates, and favorable results at medium-term (9).

In 2020, Meyer - Chapot et al published “Stenting with Acclino® (flex) for symptomatic intracranial stenosis as secondary stroke prevention”, reporting their experience with elective intracranial stenting (EICS). They retrospectively reviewed the data from three high-volume CVA centers, and they analyzed patients treated with EICS due to S-ICAD using the acclino® stent (FLEX), and Neurospeed® balloon catheter (Acandis GmbH, Pforzheim, Germany). Evaluation criteria were periprocedural CVA rates independent of the territory or death at the time of discharge and during follow-up after EICS. The safety evaluation included asymptomatic and symptomatic ICH, adverse events related to the intervention and evaluation of the permeability of the stent during follow-up. The average age of patients who complied with the inclusion criteria was 69 years. The target vessels were located in anterior circulation in 55.3% of patients. Periprocedural CVA rates were 6.5% (fatal CVA 2.6%; non-fatal CVA 3.9%) increasing after EICS, and asymptomatic ICH in 5.2% of them. Follow-up by DSA revealed intra-stent restenosis in 25%, and a new percutaneous transluminal angioplasty was performed again in 11.6% of patients. Summarizing, stent placement for S-ICAD using the acclino® (flex)/neurospeed balloon® catheter system appeared to be safe and it strengthens EICS as an endovascular therapeutic option for secondary prevention of CVA. Future studies are required to confirm these findings and to research antithrombotic strategies and restenosis in the stent to minimize periprocedural complications and guarantee permeability of the stent in the long-term (55).

Restenosis was evaluated in a recently published meta-analysis in 2020: “Incidence and Risk Factors of In-Stent Restenosis for Symptomatic Intracranial Atherosclerotic Stenosis: A

Systematic Review and Meta-Analysis”, where they analyzed all the literature that reported intra-stent stenosis in S-ICAD in PubMed, Ovid EMBASE, and Ovid MEDLINE databases. In total, they included 51 studies with 5043 patients. The combined incidence rate of intra-stent restenosis was 14.8%. Among the lesions with intra-stent restenosis, 28.8% were asymptomatic. The series in the USA had a higher intra-stent restenosis rate (27.0%) compared to Asia (13.6%). The multi regression analysis showed that the age of the youngest patients was related to high rates of stenosis in the stent ($p=0.019$), and the location of the vertebrobasilar junction ($p = 0.010$), and low residual stenosis ($p = 0.018$) were two independent risk factors for intra-stent restenosis sintomática (53).

Conclusion

In summary, substantial progress in the treatment of patients with ICAS has been achieved in the past decade, which has led to better prognosis for patients with this high-risk disease. Multidisciplinary medical treatment that incorporates short-term dual antiplatelet treatment (for 90 days), followed by monotherapy with aspirin, together with intensive treatment of vascular risk factors, is the preferred treatment for CVA prevention in these patients. In spite of this aggressive medical treatment, a large subgroup of patients still have a high risk of recurrent CVA. For them, the advancement of endovascular therapy devices are offering better effectiveness and safety rates, which explains the frequent reporting of successful treatment studies with stenting.

REFERENCES

1. Yaghi S, Prabhakaran S, Khatri P, Liebeskind DS. Intracranial Atherosclerotic Disease. *Stroke*. 2019 May;50(5):1286-1293. doi: 10.1161/STROKEAHA.118.024147. PMID: 31009344
2. Wong LK. Global burden of intracranial atherosclerosis. *Int J Stroke*. 2006;1:158–159. doi: 10.1111/j.1747-4949.2006.00045.x
3. Sacco RL, Kargman DE, Gu Q, Zamanillo MC. Race-ethnicity and determinants of intracranial atherosclerotic cerebral infarction. The Northern Manhattan Stroke Study. *Stroke* 1995; 26: 14–20.
4. Holmstedt CA, Turan TN, Chimowitz MI. Atherosclerotic intracranial arterial stenosis: risk factors, diagnosis, and treatment. *Lancet Neurol*. 2013 Nov;12(11):1106-14. doi: 10.1016/S1474-4422(13)70195-9. PMID: 24135208.
5. Chimowitz MI, Lynn MJ, Howlett-Smith H et al; Warfarin-Aspirin Symptomatic Intracranial Disease Trial Investigators. Comparison of warfarin and aspirin for symptomatic intracranial arterial stenosis. *N Engl J Med*. 2005;352:1305–1316. doi: 10.1056/NEJMoa043033

6. Prognosis of patients with symptomatic vertebral or basilar artery stenosis. The Warfarin-Aspirin Symptomatic Intracranial Disease (WASID) Study Group. *Stroke*. 1998 Jul;29(7):1389-92. doi: 10.1161/01.str.29.7.1389. PMID: 9660392.
7. Baik SH, Kwak HS, Chung GH et al. Balloon-expandable stents for treatment of symptomatic middle cerebral artery stenosis: Clinical outcomes during long-term follow-up. *Interv Neuroradiol*. 2018 Dec;24(6):666-673. doi: 10.1177/1591019918786515. PMID: 29991311; PMCID:
8. Chimowitz MI, Lynn MJ, Derdeyn CP et al; SAMMPRIS Trial Investigators. Stenting versus aggressive medical therapy for intracranial arterial stenosis. *N Engl J Med*. 2011;365:993–1003. doi: 10.1056/NEJMoa1105335
9. Salik AE, Selcuk HH, Zalov H et al. Medium-term results of undersized angioplasty and stenting for symptomatic high-grade intracranial atherosclerotic stenosis with Enterprise. *Interv Neuroradiol*. 2019 Oct;25(5):484-490. doi: 10.1177/1591019919832244. PMID: 30991867.
10. Park S, Kim JH, Kwak JK et al. Intracranial stenting for severe symptomatic stenosis: self-expandable versus balloon-expandable stents. *Interv Neuroradiol*. 2013 Sep;19(3):276-82. doi: 10.1177/159101991301900303. PMID: 24070075.
11. Feldmann E, Daneault N, Kwan E, et al. Chinese-white differences in the distribution of occlusive cerebrovascular disease. *Neurology* 1990; 40: 1541–45.
12. Chaturvedi S, Turan TN, Lynn MJ, et al. Risk factor status and vascular events in patients with symptomatic intracranial stenosis. *Neurology* 2007; 69: 2063–68.
13. Banerjee C, Chimowitz MI. Stroke caused by atherosclerosis of the major intracranial arteries. *Circ Res*. 2017;120:502–513. doi: 10.1161/CIRCRESAHA.116.308441
14. Kim DE, Kim JY, Jeong SW, et al. Association between changes in lipid profiles and progression of symptomatic intracranial atherosclerotic stenosis: a prospective multicenter study. *Stroke* 2012; 43: 1824–30.
15. Rincon F, Sacco RL, Kranwinkel G, et al. Incidence and risk factors of intracranial atherosclerotic stroke: the Northern Manhattan Stroke Study. *Cerebrovasc Dis* 2009; 28: 65–71.
16. Flusty B, de Havenon A, Prabhakaran S et al. Intracranial Atherosclerosis Treatment: Past, Present, and Future. *Stroke*. 2020 Mar;51(3):e49-e53. doi: 10.1161/STROKEAHA.119.028528. PMID: 3207844.
17. Ingall TJ, Homer D, Baker HL Jr et al. Predictors of intracranial carotid artery atherosclerosis. Duration of cigarette smoking and hypertension are more powerful than serum lipid levels. *Arch Neurol* 1991; 48: 687–91

- 1
2
3
4
5
6
7
8
9
10
11
12
13
14
15
16
17
18
19
20
21
22
23
24
25
26
27
28
29
30
31
32
33
34
35
36
37
38
39
40
41
42
43
44
45
46
47
48
49
50
51
52
53
54
55
56
57
58
59
60
61
62
63
64
65
18. Kasner SE, Chimowitz MI, Lynn MJ, et al. Predictors of ischemic stroke in the territory of a symptomatic intracranial arterial stenosis. *Circulation* 2006; **113**: 555–63.
 19. Liebeskind DS, Cotsonis GA, Saver JL, et al. Collaterals dramatically alter stroke risk in intracranial atherosclerosis. *Ann Neurol* 2011; **69**: 963–74.
 20. Bang OY, Saver JL, Ovbiagele B et al. Adiponectin levels in patients with intracranial atherosclerosis. *Neurology* 2007; 68: 1931–37.
 21. Massot A, Pelegri D, Penalba A, et al. Lipoprotein-associated phospholipase A2 testing usefulness among patients with symptomatic intracranial atherosclerotic disease. *Atherosclerosis* 2011; 218: 181–87.
 22. Arenillas JF, Alvarez-Sabin J, Molina CA, et al. Progression of symptomatic intracranial large artery atherosclerosis is associated with a proinflammatory state and impaired fibrinolysis. *Stroke* 2008; 39: 1456–63.
 23. Caplan LR. Intracranial branch atheromatous disease: a neglected, understudied, and underused concept. *Neurology* 1989; **39**: 1246–50.
 24. Schreiber S, Serdaroglu M, Schreiber F et al. Simultaneous occurrence and interaction of hypoperfusion and embolism in a patient with severe middle cerebral artery stenosis. *Stroke* 2009; 40: e478–80.
 25. Caplan LR, Hennerici M. Impaired clearance of emboli (washout) is an important link between hypoperfusion, embolism, and ischemic stroke. *Arch Neurol* 1998; 55: 1475–82.
 26. Nahab F, Cotsonis G, Lynn M et al. WASID Study Group. Prevalence and prognosis of coexistent asymptomatic intracranial stenosis. *Stroke*. 2008 Mar;39(3):1039-41. doi: 10.1161/STROKEAHA.107.499475. PMID: 18239161.
 27. Raghuram K, Durgam A, Kohlnhofer J et al. Relationship between stroke recurrence, infarct pattern, and vascular distribution in patients with symptomatic intracranial stenosis. *J Neurointerv Surg*. 2018 Dec;10(12):1161-1163. doi: 10.1136/neurintsurg-2017-013735. PMID: 29602861.
 28. Fisher CM. Lacunar strokes and infarcts: a review. *Neurology*. 1982;32: 871– 876.
 29. Khan A, Kasner SE, Lynn MJ et al. Risk factors and outcome of patients with symptomatic intracranial stenosis presenting with lacunar stroke. *Stroke* 2012; 43: 1230–33.
 30. Feldmann E, Wilterdink JL, Kosinski A, et al. The Stroke Outcomes and Neuroimaging of Intracranial Atherosclerosis (SONIA) trial. *Neurology* 2007;68:2099 –2106.
 31. Zhao L, Barlinn K, Sharma VK et al. Velocity criteria for intracranial stenosis revisited: an international multicenter study of transcranial Doppler and digital subtraction

angiography. *Stroke*. 2011 Dec;42(12):3429-34. doi: 10.1161/STROKEAHA.111.621235. PMID: 21960567.

32. Leng X, Wong KS, Liebeskind DS. Evaluating intracranial atherosclerosis rather than intracranial stenosis. *Stroke*. 2014 Feb;45(2):645-51. doi: 10.1161/STROKEAHA.113.002491. PMID: 24399377.

33. Baradaran H, Patel P, Gialdini G et al. Quantifying Intracranial Internal Carotid Artery Stenosis on MR Angiography. *AJNR Am J Neuroradiol*. 2017 May;38(5):986-990. doi: 10.3174/ajnr.A5113. PMID: 28302605.

34. Bash S, Villablanca JP, Jahan R, et al. Intracranial vascular stenosis and occlusive disease: evaluation with CT angiography, MR angiography, and digital subtraction angiography. *AJNR Am J Neuroradiol* 2005; 26: 1012–21.

35. Miteff F, Levi CR, Bateman GA et al. Parsons MW. The independent predictive utility of computed tomography angio- graphic collateral status in acute ischaemic stroke. *Brain*. 2009;132(Pt 8):2231–2238.

36. Bodle JD, Feldmann E, Swartz RH et al. High-resolution magnetic resonance imaging: an emerging tool for eval- uating intracranial arterial disease. *Stroke*. 2013;44:287–292.

37. Jia B, Liebeskind DS, Song L et al. Performance of computed tomography angiography to determine antegrade and collateral blood flow status in patients with symptomatic middle cerebral artery stenosis. *Interv Neuroradiol*. 2017 Jun;23(3):267-273. doi: 10.1177/1591019917694480. PMID: 28335662.

38. Nguyen-Huynh MN, Wintermark M, English J, et al. How accurate is CT angiography in evaluating intracranial atherosclerotic disease? *Stroke* 2008; 39: 1184–88.

39. Donahue MJ, Strother MK, Hendrikse J. Novel MRI approaches for assessing cerebral hemodynamics in ischemic cerebrovascular disease. *Stroke*. 2012;43:903–915.

40. Mandell DM, Mossa-Basha M, Qiao Y et al; Vessel Wall Imaging Study Group of the American Society of Neuroradiology. Intracranial vessel wall MRI: principles and expert consensus recommendations of the American Society of Neuroradiology. *AJNR Am J Neuroradiol*. 2017;38:218–229. doi:10.3174/ajnr.A4893

41. Samuels OB, Joseph GJ, Lynn MJ et al. A standardized method for measuring intracranial arterial stenosis. *AJNR Am J Neuroradiol* 2000; 21: 643–46.

42. Chimowitz MI, Kokkinos J, Strong J, et al. The Warfarin-Aspirin Symptomatic Intracranial Disease Study. *Neurology* 1995; 45: 1488–93.

43. Turan TN, Maidan L, Cotsonis G, et al. Failure of antithrombotic therapy and risk of stroke in patients with symptomatic intracranial stenosis. *Stroke* 2009; 40: 505–09.

44. Wang X, Lin WH, Zhao YD et al. CLAIR Study Investigators. The effectiveness of dual antiplatelet treatment in acute ischemic stroke patients with intracranial arterial stenosis: a subgroup analysis of CLAIR study. *Int J Stroke*. 2013 Dec;8(8):663-8. doi: 10.1111/j.1747-4949.2012.00828. PMID: 22883712.
45. Kwon SU, Cho YJ, Koo JS, et al. Cilostazol prevents the progression of the symptomatic intracranial arterial stenosis: the multicenter double-blind placebo-controlled trial of cilostazol in symptomatic intracranial arterial stenosis. *Stroke* 2005; 36: 782–6.
46. Mori T, Kazita K, Mori K. Cerebral angioplasty and stenting for intra- cranial vertebral atherosclerotic stenosis. *AJNR Am J Neuroradiol*. 1999; 20:787–789.
47. Lylyk P, Cohen JE, Ceratto R et al. Angioplasty and stent placement in intracranial atherosclerotic stenoses and dissections. *AJNR Am J Neuroradiol*. 2002;23:430–436.
48. Bose A, Hartmann M, Henkes H, et al. A novel, self-expanding, nitinol stent in medically refractory intracranial atherosclerotic stenoses: the Wingspan study. *Stroke* 2007; 38: 1531–37.
49. SSYL VIA Study Investigators. Stenting of Symptomatic Atherosclerotic Lesions in the Vertebral or Intracranial Arteries (SSYL VIA): study results. *Stroke*. 2004 Jun;35(6):1388-92. doi: 10.1161/01.STR.0000128708.86762.d6. PMID: 15105508.
50. Fiorella D, Levy EI, Turk AS, et al. US multicenter experience with the wingspan stent system for the treatment of intracranial atheromatous disease: periprocedural results. *Stroke* 2007; 38: 881–87.
51. Jiang WJ, Xu XT, Jin M et al. Apollo stent for symptomatic atherosclerotic intracranial stenosis: study results. *AJNR Am J Neuroradiol*. 2007 May;28(5):830-4. PMID: 17494651.
52. Zaidat OO, Klucznik R, Alexander MJ, et al. The NIH registry on use of the Wingspan stent for symptomatic 70–99% intracranial arterial stenosis. *Neurology* 2008; 70: 1518–24.
53. Fiorella D, Derdeyn CP, Lynn MJ, et al. Detailed analysis of periprocedural strokes in patients undergoing intracranial stenting in Stenting and Aggressive Medical Management for Preventing Recurrent stroke in Intracranial Stenosis (SAMMPRIS). *Stroke* 2012; 43: 2682–88.
54. Alexander MJ, Zauner A, Chaloupka JC, Baxter B, Callison RC, Gupta R, Song SS, Yu W; WEAVE Trial Sites and Interventionalists. WEAVE Trial: Final Results in 152 On-Label Patients. *Stroke*. 2019 Apr;50(4):889-894. doi: 10.1161/STROKEAHA.118.023996. PMID: 31125298.
55. Meyer L, Leischner H, Thomalla G et al. Stenting with Acclino (flex) for symptomatic intracranial stenosis as secondary stroke prevention. *J Neurointerv Surg*. 2020 Nov;12(11):1127-1131. doi: 10.1136/neurintsurg-2019-015744. PMID: 32123006.

1
2
3
4
5
6
7
8
9
10
11
12
13
14
15
16
17
18
19
20
21
22
23
24
25
26
27
28
29
30
31
32
33
34
35
36
37
38
39
40
41
42
43
44
45
46
47
48
49
50
51
52
53
54
55
56
57
58
59
60
61
62
63
64
65

Declaration of interests

☒ The authors declare that they have no known competing financial interests or personal relationships that could have appeared to influence the work reported in this paper.

☒The authors declare the following financial interests/personal relationships which may be considered as potential competing interests:

The authors mentioned in the article certify that no financial / personal interest or belief that could affect their objectivity.